Pediatric Desyndactyly

J. Joseph Anderson DPM, FACFAS; Loren K. Spencer DPM, AACFAS; Gregory Paul Rowe DPM, AACFAS; Zflan Fowler BS

NEW MEXICO BONE & JOINT INSTITUTE

AFLESR AMERICAN FOUNDATION OF LOWER EXTREMITY SURGERY AND RESEARCH

Purpose

Syndactyly of the foot can cause functional and cosmetic concerns for pediatric patients. Surgical correction of the deformity should be geared toward improving function, limiting postoperative complications, and improving the overall appearance of the foot. Full thickness skin grafts can reduce the risks of complications and contracture.

Literature Review

Syndactyly is a congenital deformity in which webbing persists between adjacent digits from birth. Syndactyly of the toes is one of the most frequently encountered congenital anomalies. It often involves the second and third toes in the foot (1). Investigators generally agree that syndactyly is caused by a rapid arrest of embryologic development from the 6th to 8th week of intrauterine life. The definitive treatment of syndactyly is surgery (2). Because the webbing between the second and third digits is the last to disappear, this area is the most sensitive to intrauterine insult (3). A recognized classification system divides the pathology into four classes: Incomplete – webbing does not extend to the most distal aspect of the involved digits, Complete – webbing extends to the ends of the involved digits, Simple – a soft tissue connection alone exists, Complicated – the phalanges are abnormal in size, shape, number, or arrangement (4). The literature represents syndactyly as a purely cosmetic problem. Surgical treatment is recommended between the ages of 2-4. Three types of surgical procedures are used in desyndactylization. They include flaps, grafts, and tissue expansion. Grafting is commonly practiced. Full-thickness skin grafts are recommended over split-thickness grafts because the split-thickness grafts are more likely to contract and deform the digits. Donor sites may include the medial submalleolar region, lateral submalleolar region, dorsum of the foot, the groin, and the abdominal region (5).

Procedure

A case study is presented on a 12-year-old male who presents with bilateral webbed feet of the 2nd and 3rd digits. He is concerned about the look of both feet and is self conscious about the appearance. He has no functional limitation. The patient was scheduled for a desyndactylization of bilateral feet with application of a full thickness skin graft. A skin marker was used to plan the surgical incision. A surgical needle was used to help plan the most proximal incision both dorsally and plantarly. Careful dissection was performed to avoid neurovascular injury of the webspace. An esmarch was used to mark the size of the full-thickness skin graft that would be needed for the webspace. A full-thickness skin graft was taken from the dorsolateral aspect of the foot and closed primarily. The full-thickness skin graft was applied to the 2nd webspace and secured with 5-0 monocryl suture. A nonadhering, meshed adaptic was placed against the graft site, and a bulky dry sterile dressing was applied to protect the graft site. The patient was seen a week after the surgery to assess the graft viability and to change the dressing due to the postoperative weeping.

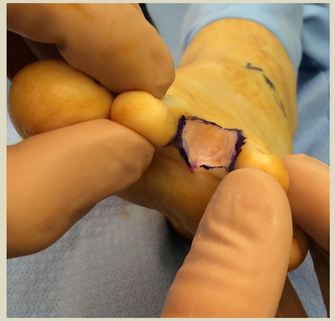

Results

The patient is 10 months postop with no complications, and he is pleased with the cosmetic results. The patient has no functional limitations or recurrence of the deformity. This case study demonstrates the benefit from using a full thickness skin graft to decreased contracture and limit soft tissue compromise at the site of correction.

Analysis/ Discussion

Although recommendations suggest doing the procedure at a younger age, this can be a very difficult decision for parents to make. Surgery always comes with risks and in some pediatric patients, other comorbidities might exists that make the syndactyly less of a priority or concern. This case study supports the thought that waiting until a child is old enough to decide with the parents can still be beneficial and the patient can have a successful outcome. The patient might have to bear some social inconveniences while growing up, but will be able to understand and elect to have the surgery performed when the patient is ready.

References

1. Park S, Eguchi T, Tokioka K, et al. Reconstruction of incomplete syndactyly of the toes using both dorsal and plantar flaps. *Plast Reconstr Surg* 1996;98:534-537.
2. Ruby L, Goldberg MJ. Syndactyly and polydactyly. *Orthop Clin North Am* 1976;7:361-374.
3. Coleman WB, Kissel CG, Sterling HD Jr. Syndactylism and its surgical repair. *J Am Podiatr Assoc* 1981;71:545-549.
4. Davis JS, German WJ. Syndactylism (coherence of the fingers or toes). *Arch Surg* 1930;21:32-75.
5. Zoltie N, Verlende P, Logan A. Full thickness grafts taken from the plantar instep for syndactyly release. *J Hand Surg Br* 1989;14:201-203.